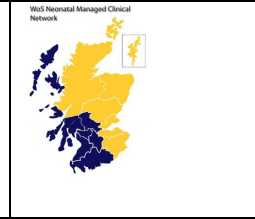


MCN for Neonatology  
West of Scotland  
Neonatal Guideline



## Cutaneous Congenital Anomalies

This document outlines the assessment and management of neonates with the following cutaneous congenital anomalies

[Capillary malformations on the face and body](#)

[Melanocytic Naevi](#)

### **Capillary Malformations on the face and body**

#### **Capillary malformation of the forehead**

Most Capillary malformations (CM) on the face arise from somatic activating mutation in the gene GNAQ. Their distribution follows the embryological vasculature rather than the trigeminal nerve distribution. Those involving the forehead (innervated by V1-3) can be associated with glaucoma, abnormal neurodevelopment and seizures while those that do not involve the forehead are not associated with those risks<sup>1</sup>. Given the severity of these neurological outcomes, there is a rationale for the diagnosis of brain involvement in asymptomatic infants with forehead CM.

Early treatment of glaucoma is critical in preserving visual function, and therefore prompt diagnosis in children with forehead CM is important as glaucoma can be present from birth.

Early diagnosis and treatment of Sturge-Weber Syndrome (SWS) may reduce disease progression and complications because the typical MRI findings of atrophy and calcification result from chronic cortical hypoxaemia due to vascular stasis and decreased perfusion in the cortex<sup>2</sup>. Although randomized controlled trials are lacking, occurrence of stroke-like episodes and seizures is reduced by administration of prophylactic aspirin<sup>3</sup>. MRI is the best predictor of all adverse clinical outcomes so that Gadolinium enhanced brain MRI should be done within the first 3 months of life. However, features of SWS can be missed through early MRI so a negative result does not exclude the development of neurological symptoms.

#### **Assessment and onward referral**

If any part of the forehead is involved, an MR with contrast as feed and wrap should be arranged as soon as possible and the child referred to ophthalmology.

If MRI is normal suggest routine paediatric follow up.

If MRI is abnormal refer to neurology for neurodevelopmental assessment and follow up and for consideration of prophylactic aspirin.

After 3 months of age MRI should be repeated only if there is a clinical suspicion of SWS.

## **CM elsewhere on the face or body**

**These are not an indication for ophthalmology assessment or contrast MR as these are not associated with a risk of glaucoma or SWS.**

Capillary Malformation can also occur in association with PIK3 mutations and in this setting are often widespread and associated with macrocephaly, sandal gap, syndactyly or polydactyly. Children with widespread CM should be referred to Dermatology.

## **Referral for treatment**

In GGC Laser treatment of facial CM is offered by the plastic surgery team in the year before school. This is expected to result in fading of the CM. Gradual darkening over years is expected and retreatment may be required. Treatment is carried out under general anaesthetic and multiple treatments are required. Treatment of hands which are also an exposed site is not associated with good treatment success and as a result is rarely offered. Referral to the plastic surgery team to discuss and plan treatment should be made from the age of three years.

1. Port-wine stain classification predicts Sturge-Weber risk, R. Waelchli et al. *British Journal of Dermatology* (2014) 171, pp861-867).
2. Miao et al. Clinical correlates of white matter blood flow perfusion changes in Sturge-Weber syndrome: a dynamic MR perfusion-weighted imaging study. *AJNR Am J Neuroradiol* 2011; 32:1280-5
3. Lance EI, Sreenivasan AK, Zabel TA et al. Aspirin use in Sturge-Weber syndrome: side effects and clinical outcomes. *J Child Neurol* 2013; 28:213-18

## Assessment and Referral of Congenital Melanocytic Naevi

Congenital melanocytic naevi (CMN) are benign collections of pigment cells (melanocytes) within the skin. Small (< 1.5-cm projected adult size) single CMN are found in around 1% of neonates<sup>1</sup>. Approximately 1 in 20 000 infants is born with a naevus of > 20-cm-diameter projected adult size<sup>2</sup>, which is then usually associated with other smaller 'satellite' CMN. Naevi grow in proportion to the child and so are expected to cover the same area of skin that is affected at birth.

Single CMN develop as a result of a somatic mutation in a variety of genes. If the mutation occurs early in development, it can affect a multipotent progenitor cell, resulting in multiple CMN on the skin and sometimes to involvement of other organ systems including the CNS<sup>3</sup>. In cases of multiple CMN, mutations in NRAS are found in 80%, with the same mutation found in all affected tissue<sup>3</sup>.

### Melanoma Risk

The overall lifetime incidence of melanoma is as low as 1–2%, with the risk in small CMN extremely low but the lifetime risk in very large (> 40 cm projected adult size) CMN, and accompanied by multiple smaller CMN, has been estimated at 10–15%<sup>4</sup>. In a substantial proportion of these cases the primary melanoma develops within the CNS rather than the skin<sup>4</sup>.

**Risk in childhood.** Risk during childhood (0–16 years) is as low as 2.2% and is seen only in children with multiple CMN with the majority in those with giant (> 60 cm projected adult size) CMN or where there are multiple CMN with no large naevus. The incidence in childhood in this group is 8%, and only 1% in those in all other groups<sup>5</sup>.

Cutaneous melanoma arising in CMN usually presents as a new nodule or lump, arising mainly in the deeper layers of the skin, and generally with a high Breslow thickness at presentation<sup>5</sup>. Children can also present with local lymphadenopathy due to metastasis.

### Referral to Dermatology

Risk in CMN < 20 cm predicted adult size is negligible and these can be monitored at home. Children with CMN > 20cm predicted adult size or with >1 CMN should be referred to dermatology.

#### Estimating predicted adult size Reference – [DermNet \(Congenital melanocytic naevus\)](#)

As a rough guide, the likely adult size of a congenital naevus can be calculated as follows:

- Lower limbs: adult size is x 3.3 size at birth
- Upper limbs/torso: adult size is x 2.8 size at birth
- Head: adult size is x 1.7 size at birth.

### Predicting Risk: Investigating children with multiple CMN

Recent data have shown an abnormal screening MRI of the CNS in the first year of life was the strongest statistical predictor of the risk of melanoma (12% in those with an abnormal MRI and 1–2% in those with a normal screening scan)<sup>5</sup>.

### Screening for Neurocutaneous outcomes in children with multiple CMN

Single CMN do not have neurological outcomes irrespective of size or site.<sup>6</sup> This means that even large CMN on the scalp do not need imaging. If there is more than one CMN of any size at birth a contrast MRI should be arranged. Kinsler et al reported that 80% of this group had a normal MRI but 10% had intraparenchymal melanosis and 10% had complex neurological abnormalities.<sup>6</sup>

Screening MRI is therefore currently the best predictor of all adverse outcomes in children with multiple CMN.

## References

1. Krengel S, Scope A, Dusza SW *et al.* New recommendations for the categorization of cutaneous features of congenital melanocytic nevi. *J Am Acad Dermatol* 2013; **68**: 441– 51
2. Castilla EE, da Graca Dutra M, Orioli-Parreiras IM. Epidemiology of congenital pigmented naevi: I. Incidence rates and relative frequencies. *Br J Dermatol* 1981; **104**: 307– 15
3. Kinsler VA, Thomas AC, Ishida M *et al.* Multiple congenital melanocytic nevi and neurocutaneous melanosis are caused by postzygotic mutations in codon 61 of NRAS. *J Invest Dermatol* 2013; **133**: 2229– 36
4. Krengel S, Hauschild A, Schafer T. Melanoma risk in congenital melanocytic naevi: a systematic review. *Br J Dermatol* 2006; **155**: 1– 8.
5. Waelchli R, Aylett SE, Atherton D *et al.* Classification of neurological abnormalities in children with congenital melanocytic naevus syndrome identifies magnetic resonance imaging as the best predictor of clinical outcome. *Br J Dermatol* 2015; **173**: 739– 50.
6. Kinsler et al 2017

## Document name

WoS\_Cutaneousanomalies\_Neonates

## Author

Dr Paula Beattie – Consultant Dermatologist, RHC, Glasgow

Dr Andrew Powls – Consultant Neonatologist, PRM, Glasgow

## Implementation / Review Dates

Implementation 01/01/23

Review Date 01/01/26